

## Case Report

# A Fulminant Case of Meningococemia with Meningococcal Meningitis in 3-Year-Old Child

Parag Hasmukhbhai Shah<sup>1</sup>, Sultan Al Busaidi<sup>1</sup>, Ahmed Al MUSAIKHI<sup>1</sup>

<sup>1</sup>Department of Communicable Disease Control, Directorate of Disease Surveillance and Control, Ministry of Health, North Sharqiya, Sultanate of Oman.

### \*Corresponding author:

Parag Hasmukhbhai Shah,  
Epidemiologist and Head of  
Communicable disease Control  
section at Directorate of Disease  
Surveillance and Control, North  
Sharqiya, Ministry of Health,  
Sultanate of Oman.

[parag\\_h\\_shah@yahoo.com](mailto:parag_h_shah@yahoo.com)

Received: 11 December 2024  
Accepted: 10 January 2025  
Epub Ahead of Print: 10 March 2025  
Published: 26 March 2025

DOI  
[10.25259/JCH\\_64\\_2024](https://doi.org/10.25259/JCH_64_2024)

### Quick Response Code:



## ABSTRACT

Meningococcal meningitis is caused by gram-negative diplococci named *Neisseria meningitidis*. The most common symptoms are a stiff neck, high fever, photosensitivity, confusion, headaches, and vomiting. Meningococemia is the most severe form of infection with petechial rash, hypotension, disseminated intravascular coagulation, and multi-organ failure. Early antibiotic treatment is the most important measure to save lives and reduce complications. The case presented here is A 3-year-old female child admitted to a secondary hospital in the province of North Sharqiya, Sultanate of Oman with fever and purpuric ecchymosis rash all over the body. The symptoms started as a fever 1 day before admission and the next day she developed a purpuric rash. She did not have any other comorbidity and vaccination was proper as per age. Condition deteriorated drastically even after aggressive treatment and resuscitation at a secondary care hospital. She died on the same day of admission. The reverse transcription polymerase chain reaction of blood detected Meningococcal infection. Case notified to public health authorities and rapid response was carried out in the form of field investigation and providing chemoprophylaxis to all close contacts. No secondary cases were found after 2 weeks of index cases.

**Keywords:** Disseminated intravascular coagulation, Ecchymosis rash, Meningococemia, Meningococcal meningitis, Polysaccharide, Quadivalent, Reverse transcription polymerase chain reaction

## INTRODUCTION

Meningococcal meningitis is caused by Gram-negative diplococci named *Neisseria meningitidis*.<sup>1</sup> Meningococcal meningitis is observed worldwide but the highest burden of the disease is in the meningitis belt of sub-Saharan Africa, stretching from Senegal in the west to Ethiopia in the east. Around 30,000 cases are still reported each year from that area.<sup>1,2</sup> Twelve types of *Neisseria meningitidis*, called serogroups, have been identified, six of which (A, B, C, W, X, and Y) can cause epidemics.<sup>1,2</sup> Invasive disease is characterized by one or more clinical syndromes including bacteremia, sepsis, or meningitis. Meningococemia is the most severe form of infection with petechial rash, hypotension, disseminated intravascular coagulation (DIC), and multi-organ failure. Other forms of meningococemia may include pneumonia, purulent arthritis and pericarditis.<sup>2</sup> Meningococcal meningitis is associated with a high case fatality rate of 8–15% (up to 50% when untreated), early antibiotic treatment is the most important measure to save lives and reduce complications.<sup>1</sup> Meningococcal meningitis is an important notifiable communicable disease in Oman due to the associated mortality and a potential risk of epidemic.

This is an open-access article distributed under the terms of the Creative Commons Attribution-Non Commercial-Share Alike 4.0 License, which allows others to remix, transform, and build upon the work non-commercially, as long as the author is credited and the new creations are licensed under the identical terms.

©2025 Published by Scientific Scholar on behalf of Journal of Comprehensive Health

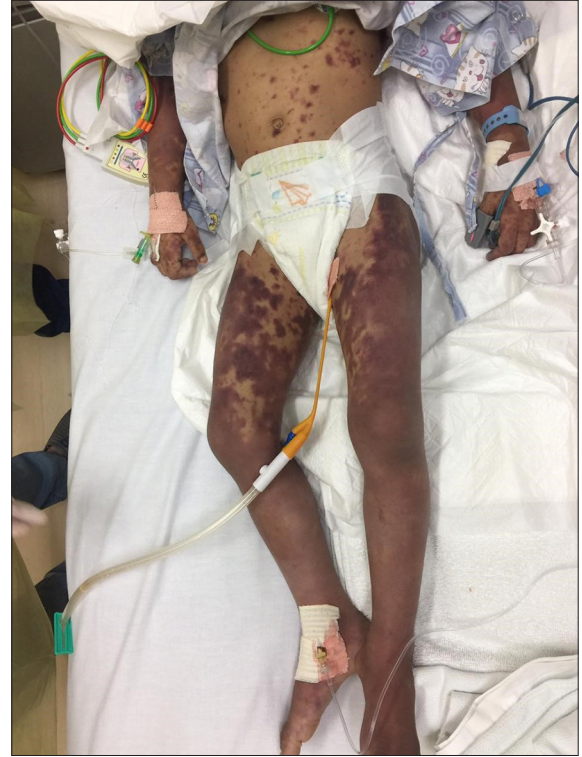## CASE REPORT

A 3-year-old female Omani child presented with fever and purpura with petechial and ecchymotic rash all over the body at a secondary care hospital in the Sultanate of Oman. She is fully vaccinated according to her age and not associated comorbidity. Her weight was 10 kg and no previous admission due to any other cause. The rash was initially reddish, later becoming bluish black. On history, the patient got a fever on November 14, 2019, and it was high grade. On November 15, 2019, the patient started getting a purpuric rash on all over the body in the morning, so she was taken to the district hospital. The examining doctor noticed a typical purpuric non-blanching ecchymosis rash on the trunk and limbs as well as hemorrhagic spots in the conjunctiva. As shown in Figures 1 and 2, typical petechial rash is very crucial and pathognomonic to make clinical diagnosis of meningococcal meningitis. The patient was immediately put under isolation as a treating specialist suspected meningococemia. On investigation, white blood cells were  $20.24 (10 \times 3 \text{ e/uL})$ , with high neutrophils in blood at  $14.15 \text{ cells uL}$ . The platelet was found to be  $54.25 (10 \times 3 \text{ e/uL})$ . The coagulation profile was dearranged prothrombin time (PT) and activated partial thromboplastin time (APTT) with high C-reactive protein and high aspartate transaminase in liver function test. All infection control measures were taken. The patient was isolated in the intensive care unit and put on a ventilator. A parenteral agent was given to increase blood pressure.

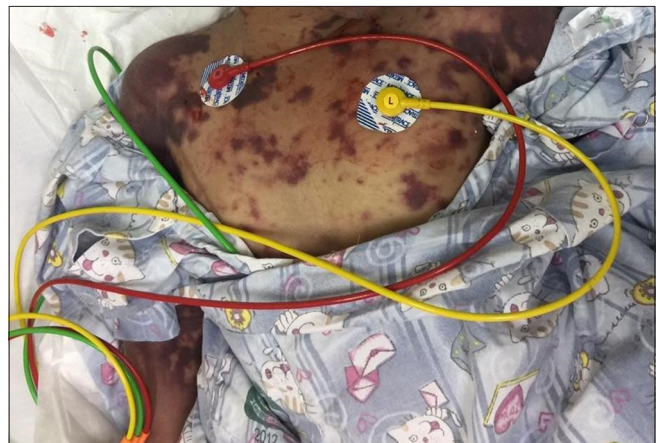
The blood samples were collected and sent to the Central Public Health Laboratory in Muscat for investigation. A reverse transcription polymerase chain reaction (PCR) test detected *Neisseria meningitidis*. Serogrouping of the organism was done using real-time in-house PCR with Centers for Disease Control and Prevention recommended primers and probes and it was untypable (non-A, B, C, Y, and W135).<sup>3</sup> The patient died within 1 h of admission to a regional hospital. The dead body was handled with proper infection control measures. There were no meningococcal meningitis cases reported in the hospital in the past 3 years. Hence, this was the first case in the state, so the rapid response team of the province was activated immediately and an epidemiological investigation was carried out. The patient had no travel history outside the Sultanate of Oman and she had not come in contact with any symptomatic case in the recent past. No one from the family has had hospital admission recently. The close family members were counseled and provided with chemoprophylaxis of ciprofloxacin single dose (500 mg) for adults on the same day of diagnosis. The pediatric close contacts were provided with intramuscular (IM) ceftriaxone. All contacts were followed for 2 weeks daily and none of them developed any symptoms.

## DISCUSSION

*Neisseria meningitidis* is the most common forms of



**Figure 1:** Petechial rash on leg.



**Figure 2:** Petechial rash on chest.

*Neisseria meningitidis* and meningococemia. It is usually transmitted by the respiratory route. The incidence of endemic meningococcal disease during the past 13 years ranges from 1 to 5/100,000 in developed countries, and from 10 to 25/100,000 in developing countries.<sup>3</sup>

The average incubation period is four days but can range between 2 and 10 days. Meningococemia, like many other Gram-negative blood infections, can cause DIC, which is the inappropriate clotting of blood within the vessels.<sup>3</sup> Even when the disease is diagnosed early and adequate treatment is started, 8–15% of patients die, often

within 24–48 h after the onset of symptoms. If untreated, meningococcal meningitis is fatal in 50% of cases and may result in brain damage, hearing loss, or disability in 10–20% of survivors.<sup>4</sup>

The case presented here had a typical purpuric non-blanching rash but she developed meningococemia and multi-organ failure within 24 h of starting of fever, which was the cause of death, even though IV antibiotics were administered at an early stage. It is also noted that in some meningococemia cases, the duration from fever to death is as short as 12 h.<sup>5</sup>

A systematic review compared two antibiotics ceftriaxone (in which there were 14 deaths out of 247), and chloramphenicol (12 deaths out of 256) shown good results. Antibiotic choice should be based on local antibiotic resistance information.<sup>6</sup>

Person-to-person transmission can be interrupted by chemoprophylaxis, which eradicates the asymptomatic nasopharyngeal carrier state.<sup>7</sup>

Two types of quadrivalent (Serogroups A, C, W-135, and Y) vaccines are available in the market to prevent meningococcal disease. One is polysaccharide which is effective for around 3 years and the other is conjugate which is effective for 5 years.<sup>8</sup> Suspected cases of meningitis under high-priority diseases and need to be notified under the electronic notification system in the Sultanate of Oman within 24 h.<sup>2</sup>

As many as 10% of adolescents and adults are asymptomatic transient carriers of *N. meningitidis*, most strains of which are not pathogenic.<sup>8</sup> It has been noted that effective vaccination does not prevent nasopharyngeal carriage state. Hence, the person may transmit infection to others. Asymptomatic nasal carrier is the most common source of infection in countries where it is not endemic.<sup>9,10</sup>

## CONCLUSION

Meningococemia is a highly fatal disease if not treated on time and in certain situations encountered in the presented case it was fatal even if promptly treated. It is important that clinicians promptly report all cases of suspected or confirmed meningococcal disease to local public health authorities. Chemoprophylaxis is highly recommended for close contacts to prevent transmission in the community. Asymptomatic nasal carrier is a very common phenomenon in most endemic countries, so it is very difficult to prevent the risk of transmission to non-endemic countries. All at-risk individuals including travelers to endemic countries and healthcare workers should receive immunization against meningococcal disease mainly laboratory personnel who are routinely exposed to isolates of *N. meningitidis*.

**Ethical approval:** The Institutional Review Board approval has been obtained.

**Declaration of patient consent:** The authors certify that they have obtained all appropriate patient consent.

**Financial support and sponsorship:** Nil.

**Conflicts of interest:** There are no conflicts of interest.

**Use of artificial intelligence (AI)-assisted technology for manuscript preparation:** The authors confirm that there was no use of artificial intelligence (AI)-assisted technology for assisting in the writing or editing of the manuscript and no images were manipulated using AI.

## REFERENCES

1. WHO Face Sheet on Meningococcal Meningitis. Available from: <https://www.who.int/news-room/fact-sheets/detail/meningococcal-meningitis> [Last accessed on 2024 Dec 05].
2. Communicable Disease Surveillance Manual, Ministry of Health, Sultanate of Oman; 2017. p. 74.
3. Shaker R, Fayad D, Dbaibo G. Challenges and Opportunities for Meningococcal Vaccination in the Developing World. *Hum Vaccin Immunother* 2018;14:1084-97.
4. Meningococcal Septicaemia in College Students. Essortment; 2002. Available from: [https://web.archive.org/web/20070728015234/http://ncnc.essortment.com/meningitissepti\\_ride.htm](https://web.archive.org/web/20070728015234/http://ncnc.essortment.com/meningitissepti_ride.htm) [Last accessed on 2008 Jan 29].
5. Clegg HW, Todres ID, Moylan FM, Keim DE, Shannon DC. Fulminant Neonatal Meningococemia. *Am J Dis Child* 1980;134:354-5.
6. Sudarsanam TD, Rupali P, Tharyan P, Abraham OC, Thomas K. Pre-admission Antibiotics for Suspected Cases of Meningococcal Disease. *Cochrane Database Syst Rev* 2017;6:CD005437.
7. Chapter 14 - Meningococcal Disease Center of Disease Control -Pink Book. <https://www.cdc.gov/pinkbook/hcp/table-of-contents/chapter-14-meningococcal-disease.html> [Last accessed on 2024 Dec 05].
8. Meningococcal Vaccination - What You Should Know. Centers for Disease Control and Prevention (CDC); 2019. Available from: <https://web.archive.org/web/20191020052155/https://www.cdc.gov/vaccines/vpd/mening/public/index.html> [Last accessed on 2019 Oct 19].
9. Meningococcal Vaccine - World Health Organisation - <https://www.who.int/teams/health-product-policy-and-standards/standards-and-specifications/norms-and-standards/vaccine-standardization/meningococcal-meningitis> [Last accessed on 2024 Dec 05].
10. Laboratory Methods on diagnosis of Meningitis caused by *Neisseria meningitidis* - Second edition 2011, WHO and CDC. [https://iris.who.int/bitstream/10665/70765/1/WHO\\_IVB\\_11.09\\_eng.pdf](https://iris.who.int/bitstream/10665/70765/1/WHO_IVB_11.09_eng.pdf) [Last accessed on 2024 Dec 05].

**How to cite this article:** Shah PH, Al Busaidi SA, Al Musaikhi AO. A Fulminant Case of Meningococemia with Meningococcal Meningitis in 3-Year-Old Child. *J Compr Health*. 2025;13:86-8. doi: 10.25259/JCH\_64\_2024